

From the Society for Clinical Vascular Surgery

A multi-institutional experience in the aortic and arterial pathology in individuals with genetically confirmed vascular Ehlers-Danlos syndrome

Sherene Shalhub, MD, MPH, FACS,^a Peter H. Byers, MD,^b Kelli L. Hicks, BS,^a Kristofer Charlton-Ouw, MD,^c Devin Zarkowsky, MD,^d Dawn M. Coleman, MD,^e Frank M. Davis, MD,^e Ellen S. Regalado, MS, CGC,^f Giovanni De Caridi, MD, PhD,^g K. Nicole Weaver, MD,^h Erin M. Miller, MS, LGC,ⁱ Marc L. Schermerhorn, MD,^j Katie Shean, MD,^j Gustavo Oderich, MD,^k Mauricio Ribeiro, MD, PhD,^l Cole Nishikawa, MD,^m Christian-Alexander Behrendt, MD,ⁿ E. Sebastian Debus, MD, PhD,^o Yskert von Kodolitsch, MD,^o Richard J. Powell, MD,^p Melanie Pepin, MS, CGC,^b Dianna M. Milewicz, MD, PhD,^f Peter F. Lawrence, MD,^q and Karen Woo, MD, MS,^q *Seattle, Wash; Houston, Tex; San Francisco, Los Angeles, and Sacramento, Calif; Ann Arbor, Mich; Messina, Italy; Cincinnati, Ohio; Boston, Mass; Rochester, Minn; São Paulo, Brazil; Hamburg, Germany; and Lebanon, NH*

ABSTRACT

Objective: Vascular Ehlers-Danlos syndrome (vEDS) is a rare connective tissue disorder owing to pathogenic variants in *COL3A1* that lead to impaired type III collagen production. We aim to describe the contemporary multi-institutional experience of aortic and arterial pathology in individuals with vEDS, to evaluate disease patterns and refine management recommendations.

Methods: This cross-sectional, retrospective study of individuals with genetically confirmed vEDS was conducted between 2000 and 2015 at multiple institutions participating in the Vascular Low Frequency Disease Consortium. Aortic and arterial events including aneurysms, pseudoaneurysms, dissections, fistulae, or ruptures were studied. Demographics, *COL3A1* variants, management, and outcomes data were collected and analyzed. Individuals with and without arterial events were compared.

Results: Eleven institutions identified 86 individuals with pathogenic variants in *COL3A1* (47.7% male, 86% Caucasian; median age, 41 years; interquartile range [IQR], 31.0-49.5 years; 65.1% missense *COL3A1* variants). The median follow-up from the time of vEDS diagnosis was 7.5 years (IQR, 3.5-12.0 years). A total of 139 aortic/arterial pathologies were diagnosed in 53 individuals (61.6%; 50.9% male; 88.5% Caucasian; median age, 33 years; IQR, 25.0-42.3 years). The aortic/arterial events presented as an emergency in 52 cases (37.4%). The most commonly affected arteries were the mesenteric arteries (31.7%), followed by cerebrovascular (16.5%), iliac (16.5%), and renal arteries (12.2%). The most common management was medical management. When undertaken, the predominant endovascular interventions were arterial embolization of medium sized arteries (13.4%), followed by stenting (2.5%). Aortic pathology was noted in 17 individuals (32%; 58.8% male; 94.1% Caucasian; median age, 38.5 years; IQR, 30.8-44.7 years). Most notably, four individuals underwent successful abdominal aortic aneurysm repair with excellent results on follow-up. Individuals with missense mutations, in which

From the Division of Vascular Surgery, Department of Surgery,^a and Departments of Pathology and Medicine (Medical Genetics),^b University of Washington School of Medicine, Seattle; the Department of Cardiothoracic and Vascular Surgery,^c and Division of Medical Genetics, Department of Internal Medicine,^d University of Texas Health Science Center at Houston, Houston; the Division of Vascular and Endovascular Surgery, Department of Surgery, University of California San Francisco, San Francisco^e; the Section of Vascular Surgery, Department of Surgery, University of Michigan, Ann Arbor^f; the Department of Cardiovascular and Thoracic Sciences, University of Messina, Messina^g; the Division of Human Genetics, Cincinnati Children's Hospital Medical Center,^h and the Divisions of Cardiology and Human Genetics, University of Cincinnati School of Medicine and Cincinnati Children's Hospital Medical Center,ⁱ Cincinnati; the Division of Vascular and Endovascular Surgery, Beth Israel Deaconess Medical Center, Boston^j; the Division of Vascular Surgery, Mayo Clinic, Rochester^k; the Division of Vascular and Endovascular Surgery, Department of Surgery and Anatomy, Medical School of Ribeirão Preto, University of São Paulo, São Paulo^l; the Department of Surgery, University of California, Davis Medical Center, Sacramento^m; the Department of Vascular Medicine,ⁿ and Department of Cardiology,^o University Heart Center Hamburg, University Medical Center Hamburg-Eppendorf, Hamburg; the Division of Vascular Surgery, Dartmouth-Hitchcock Medical Center,

Lebanon^p; and the Division of Vascular Surgery, University of California Los Angeles, Los Angeles.^q

Author conflict of interest: none.

Supported in part the National Center for Advancing Translational Sciences of the National Institutes of Health under Award Number UL1TR000423 (S.S.), in part by funds from the Freudmann Fund for Translational Research in Ehlers-Danlos syndrome at the University of Washington (P.H.B.), and in part by the National Institutes of Health (NIDDK 1K08DK107934) (K.W.). The content is solely the responsibility of the authors and does not necessarily represent the official views of the National Institutes of Health.

Presented at the Forty-fifth Annual Symposium of the Society for Clinical Vascular Surgery, Las Vegas, Nev, March 18-22, 2017.

Correspondence: Sherene Shalhub, MD, MPH, FACS, Division of Vascular Surgery, Department of General Surgery, University of Washington School of Medicine, 1959 N.E. Pacific ST, Box 356410, Seattle, WA 98195 (e-mail: shalhub@uw.edu).

The editors and reviewers of this article have no relevant financial relationships to disclose per the JVS policy that requires reviewers to decline review of any manuscript for which they may have a conflict of interest.

0741-5214

Copyright © 2019 by the Society for Vascular Surgery. Published by Elsevier Inc. <https://doi.org/10.1016/j.jvs.2019.01.069>

glycine was substituted with a large amino acid, had an earlier onset of aortic/arterial pathology (median age, 30 years; IQR, 23.5-37 years) compared with the other pathogenic *COL3A1* variants (median age, 36 years; IQR, 29.5-44.8 years; $P = .065$). There were 12 deaths (22.6%) at a median age of 36 years (IQR, 28-51 years).

Conclusions: Most of the vEDS arterial manifestations were managed medically in this cohort. When intervention is required for an enlarging aneurysm or rupture, embolization, and less frequently stenting, seem to be well-tolerated. Open repair of abdominal aortic aneurysm seems to be as well-tolerated as in those without vEDS; vEDS should not be a deterrent to offering an operation. Future work to elucidate the role of surgical interventions and refine management recommendations in the context of patient centered outcomes is warranted. (J Vasc Surg 2019;■■:1-12.)

Keywords: Vascular Ehlers-Danlos syndrome; *COL3A1* mutation; Arterial dissection; Arterial aneurysm; Arterial rupture

Vascular Ehlers-Danlos syndrome (vEDS) is a rare syndrome in which type III collagen production is reduced or the collagen produced is defective because of autosomal-dominant mutations in *COL3A1*.¹⁻³ The syndrome, which was previously called Ehlers-Danlos syndrome type IV, is 1 of 13 subtypes of Ehlers-Danlos syndrome.⁴ In addition to spontaneous intestinal perforation or rupture of a gravid uterus, the hallmark of the disease is spontaneous arterial dissections, aneurysms, and rupture at a young age.^{1,2,5}

Up to 40% of individuals with vEDS experience their first major arterial complication by the age of 40.^{2,6} The classically reported arteries include mesenteric, renal, iliac, femoral, and/or the abdominal aorta, followed by the carotid, subclavian, ulnar, popliteal, and tibial arteries.⁷ A spontaneous carotid-cavernous fistula (CCF) is pathognomonic of vEDS and estimated to occur in 9.8% of individuals with vEDS.⁸

The predominant challenges to studying vEDS are driven by the rarity of the disease, the heterogeneous presentation of aortic and arterial pathology, the large number of pathogenic variants in *COL3A1* leading to vEDS, a lack of robust longitudinal data, and underdiagnosis or misdiagnosis. Although we have a basic understanding of the natural history of the disease based on seminal work² and a limited understanding of the genotype-phenotype correlation,^{6,9-11} we do not have a detailed natural history of aortic and arterial aneurysms and dissections in this population, nor do we have a clear understanding of the risk of complications, once diagnosed and treated.¹² The aim of this study was to describe the contemporary multi-institutional experience of aortic and arterial pathology in individuals with vEDS, evaluate disease patterns, and refine management recommendations to improve our understanding of genotype-phenotype correlations.

METHODS

The Vascular Low Frequency Disease Consortium. This multi-institutional retrospective cross-sectional cohort study of individuals diagnosed with vEDS was conducted between January 1, 2000, and December 31, 2015. The 11 institutions were recruited through the Vascular Low Frequency Disease Consortium (University of California-Los Angeles Division of Vascular Surgery).¹³ Each participating center obtained its own institutional review board

approval. The institutional review boards waived the patient consent process owing to minimal patient risk. Data were collected by each institute's respective investigator(s), deidentified, and then submitted and stored using a password-encrypted database maintained by the University of Washington.

Identification of individuals with vEDS and inclusion and exclusion criteria. Individuals were initially identified with *International Classification of Diseases-9-CM* code 756.83 or *International Classification of Diseases-10-CM* code Q79.6 for Ehlers-Danlos syndrome. Confirmatory molecular testing results were then reviewed by a geneticist (P.H.B.) to confirm that the *COL3A1* variant is a pathogenic variant in keeping with the ACMG guidelines.^{2,9,10} Individuals were included for analysis only if they had a pathogenic variant in *COL3A1*. The pathogenic *COL3A1* variants were grouped into missense mutations (glycine substitutions), exon skip and splice site variants, and haploinsufficiency (null mutations).^{6,9-11,14-16} The type of amino acid substitution was noted as a large or small amino acid.^{6,15}

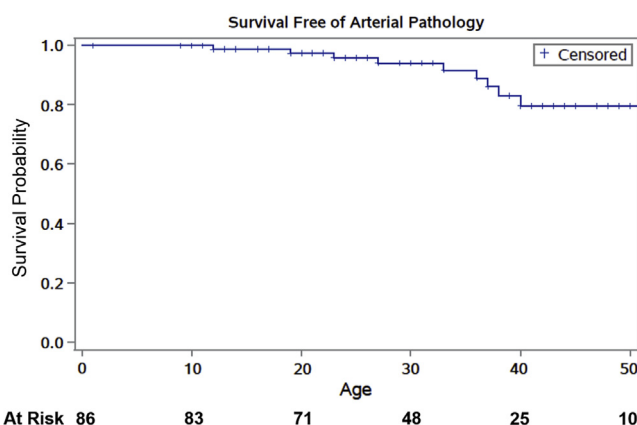
Demographics, current age, age at diagnosis, family history, clinical diagnostic criteria,¹⁷ aortic and arterial pathology, management of aortic and arterial pathology, and outcomes were collected. Family history was defined as a family history of vEDS, aortic or arterial aneurysms and dissections, and/or sudden death. Arterial pathology included aortic and arterial aneurysms, dissections, pseudoaneurysms, fistulae, thrombosis, or ruptures. Arterial pathology was noted as emergent if it was life threatening on presentation. This category included aortic or arterial rupture, symptomatic aortic/arterial dissections, and CCF.

Given that subject data were collected locally at each participating institution and then submitted as de-identified data to the consortium, a comparison of all the presentations, *COL3A1* variants, and demographics was performed to ensure that there were no duplicated cases. Data were analyzed using Microsoft Excel 2007 software (Microsoft, Redmond, Wash) and SPSS version 19 for Windows (SPSS, Inc., Chicago, Ill). Continuous data are presented as medians and interquartile ranges (IQRs). Continuous data were compared using Wilcoxon rank-sum (Mann-Whitney) test. Categorical data were compared by a χ^2 or Fisher's exact test where

Table 1. A comparison of individuals with vascular Ehlers-Danlos syndrome (vEDS) with and without a diagnosis of aortic/arterial pathology

	Aortic/Arterial pathology (n = 53)	No aortic/arterial pathology (n = 33)	P value
Current age	41 [31-49.5]	25 [15-41.5]	<.001
Age range	19-79	1-88	—
Age at diagnosis	32 [23-43.3]	18 [10-31]	<.001
Male sex	27 (50.9)	14 (42.4)	.442
Caucasian	47 (88.7)	27 (81.8)	.491
BMI	24.6 [21.6-27.4]	22.9 [17.1-25.3]	.068
Hypertension	17 (32.1)	2 (6.1)	.005
Deep vein thrombosis	12 (22.6)	1 (3)	.014
Intestinal perforation	9 (17)	5 (15.2)	.823
Spontaneous PTX/HTX	7 (13.2)	5 (15.2)	.800
Current or past smoker	12 (22.6)	5 (15.2)	.396
Family history of VEDS	24 (45.3)	18 (54.5)	.403
Follow-up after vEDS diagnosis	7.5 [3.5-12]	5 [1-11]	.152
Died	13 (24.5)	0	.002
Age at death	39 [27.8-51.3]	—	—

BMI, Body mass index; HTX, hemothorax; PTX, pneumothorax; vEDS, vascular Ehlers-Danlos syndrome.
Values are number (%) or median [interquartile range].

**Fig 1.** Kaplan-Meier estimates of cumulative survival free of any arterial pathology in a cohort of individuals with vascular Ehlers-Danlos syndrome (vEDS).

appropriate. The comparisons of the onset of the arterial pathology and survival were performed using Kaplan-Meier survival curves with the log-rank test. All statistical tests were two-sided and a *P* value of less than .05 was considered statistically significant.

RESULTS

Eighty-six individuals had molecular confirmation of vEDS (47.7% male; 86% Caucasian; median age, 41 years; IQR, 31.0-49.5 years; range, 1-88 years). The cohort

ARTICLE HIGHLIGHTS

- **Type of Research:** Cross-sectional retrospective study of the Vascular Low Frequency Disease Consortium
- **Key Findings:** In this group of 86 individuals with genetically confirmed vascular Ehlers-Danlos syndrome, with pathogenic COL3A1 variants, most patients were managed medically. For treatment of an enlarging aneurysm or rupture, embolization and stenting were well-tolerated. Four patients underwent successful open abdominal aortic aneurysm repair.
- **Take Home Message:** Genetic confirmation of pathogenic COL3A1 variants of vascular Ehlers-Danlos syndrome is essential for counseling affected individuals on the effect of their variant type and directing care. When intervention is required, embolization and stenting are acceptable options. Open repair of abdominal aortic aneurysms is also well-tolerated.

included 19 individuals (22.1%) who were diagnosed as children (age <18 years old). The median follow-up from the time of vEDS diagnosis was 7.5 years (IQR, 3.5-12.0 years).

A total of 139 aortic/arterial pathologies were diagnosed in 53 individuals (61.6%; 50.9% male; 88.5% Caucasian; median age 33 years; IQR, 25.0-42.3 years). The aortic/arterial events presented as an emergency in 52 cases (37.4%).

The diagnosis of vEDS was already established in 20 individuals (37.3%) before the diagnosis of aortic/arterial pathology. The diagnosis of vEDS was less likely to be known in the emergent setting compared with the elective setting (18.2% vs 55.2%; *P* = .007).

There were no differences between men and women in the age of the initial aortic/arterial pathology diagnosis (median, 32 years [IQR, 23-42 years] among men; median, 36 years [IQR, 26.8-43.3 years] among women; *P* = .393), or the time of first aortic/arterial rupture (median, 33 years [IQR, 15.5-49.0 years] among men; median, 39 years [IQR, 30.0-46.7 years] among women; *P* = .540). The individuals with aortic/arterial pathology were significantly older than those without (Table 1). In addition, the group without aortic/arterial pathology included 14 children compared with only one child who presented with type B aortic dissection at 12 years of age (had missense mutation, p.Gly244Arg). Those patients with aortic/arterial pathology had more hypertension and deep vein thrombosis. There were no differences in the type of pathogenic COL3A1 variants or minor clinical diagnostic criteria between those with and without aortic/arterial pathology, with the exception of a lower frequency of hypermobile small joints (32.1% vs 54.5%; *P* = .039).

Table II. Presentation and management of arterial pathology in patients with vascular Ehlers-Danlos syndrome (vEDS) by artery involved

Arteries, No. (%)	Male, %	Median age (IQR)	Known vEDS diagnosis	Missense mutation	Dissection
Carotid, 17 (12.2)	5 (41.7)	27 (24-36)	4 (33.3)	8 (66.7)	6 (50)
Vertebral, 6 (4.3)	2 (33.3)	27.5 (22-32.5)	3 (50)	5 (83.3)	4 (66.6)
Celiac, 14 (10.5)	6 (40)	44 (33-50)	12 (80)	11 (73.3)	7 (46.7)
Gastric, 3 (2.2)	0	37 (36-37)	2 (66.7)	2 (66.7)	1 (33.3)
Phrenic, 1 (0.7)	0	58	1 (100)	1 (100)	0
Splenic, 11 (7.9)	3 (27.3)	44 (31-51)	6 (54.5)	6 (54.5)	2 (18.2)
Hepatic, 8 (5.8)	5 (62.5)	47 (38.5-50.5)	5 (62.5)	4 (50)	0
Superior mesenteric, 6 (4.3)	1 (16.7)	45.5 (39-54.4)	5 (83.3)	3 (50)	2 (33.3)
Renal, 17 (12.2)	12 (70.6)	37 (30.5-41)	9 (52.9)	13 (76.5)	7 (41.2)
Iliac, 23 (16.5)	18 (78.3)	41 (30-48)	12 (52.2)	19 (82.6)	7 (30.4)
Femoral, 2 (1.4)	1 (50)	27 (33)	0	2 (100)	1
Popliteal, 1 (0.7)	0	26	0	1 (100)	0
Posterior tibial, 3 (2.2) ^b	2 (100)	19 (32)	1 (50)	1 (50)	0

IQR, Interquartile range.

The percent given is the percentage of all arterial pathology.

^aSame individual, death owing to multiple mesenteric arterial ruptures.^bOne individual had bilateral posterior tibial arteries aneurysms.

Arterial pathology. The most commonly affected arteries were the mesenteric arteries (31.7%), followed by cerebrovascular and iliac arteries (16.5% each), and renal arteries (12.2%). Arterial pathology included aneurysms (53.8%), dissections (35.3%), rupture (10.1%), pseudoaneurysms (3.4%), thrombosis (2.5%), and CCF (4.2%). Fig 1 shows the Kaplan-Meier estimates of cumulative survival free of any arterial pathology. Table II summarizes the presentation and management of the arterial pathologies.

- **Carotid cavernous fistulae.** CCF occurred in four individuals (Table III). Management was predominantly via embolization with satisfactory outcomes (Fig 2). None of the CCFs were associated with mortality.
- **Carotid and vertebral pathology other than CCF.** These patients presented with small aneurysms or dissections. All were managed medically, as detailed in Table II. Most had no complications, with the exception of one patient with a vertebral artery dissection leading to a lateral medullary infarct and death.
- **Mesenteric arteries.** The celiac artery was the most commonly affected mesenteric artery (Fig 3); however, the splenic artery was most frequently affected by rupture (36.4%). Medical management was the most common approach (Table II), with the exception of cases in which rupture or pseudoaneurysms occurred. These cases were treated most commonly with endovascular embolization, and in one case with stenting (Fig 4), with satisfactory results. There was one mortality in this group (a patient who presented with multiple mesenteric arterial ruptures).
- **Renal arteries.** Renal arteries presented with nearly equal frequency of dissections and aneurysms.

Aneurysm sizes were recorded in four cases (0.8, 0.8, 1.2, and 3 cm). The predominant approach to treatment was medical management (Table II), with the exception of two patients requiring intervention: a 40-year-old man who underwent embolization (no additional detail) and a 29-year-old man (c.1124G>A, p.Gly375Glu), who presented with left renal artery thrombosis that was treated with thrombolysis. This approach was complicated by splenic hemorrhage requiring a splenectomy. He presented 5 months later with aneurysmal degeneration of the renal artery and underwent a successful nephrectomy (6 years of follow-up).

- **Iliac arteries.** Twenty-three common, external, and internal iliac arteries had pathology, which was diagnosed as isolated iliac disease in nine (16.9%), and in association with abdominal aortic aneurysm (AAA) in eight (15.1%) individuals (Table II). Most were managed medically. Stenting was performed in two cases (c.3847C>T, p.Gln1283Ter and c.3320G>A, Gly107Glu) for common iliac artery aneurysms, using femoral artery exposure and stent repair, with satisfactory results. Open iliac repair was performed in three cases.
 - For an iliac artery rupture in a 50-year-old man (c.1295G>A, p.Gly432Asp), which was complicated with postoperative wound dehiscence with the development of an enterocutaneous fistula.
 - For an iliac artery dissection with thrombosis treated with an uncomplicated iliofemoral bypass in a 30-year-old man (c.674G>C, p.Gly225Ala). The patient has had 6 years of follow-up after the procedure without complication.
 - For an iliac artery aneurysm treated with an uncomplicated open bypass in a 41-year-old man

Table II. Continued.

Aneurysm, pseudoaneurysm	Rupture	Medical management	Endovascular embolization	Endovascular stenting	Open repair
5 (41.7), 1 (8.3)	0	100%	0	0	0
1 (16.7)	0	100%	0	0	0
7 (46.7), 2 (13.3)	2 (13.3)	13 (86.7)	1 (6.7) ^a	0	1 (6.7)
0	0	3 (100)	0	0	0
1 (100)	0	1 (100)	0	0	0
8 (72.7)	4 (36.4)	4 (36.4)	6 (54.5)	0	1 (9.4)
7 (87.5), 1 (12.5)	1 (12.5)	5 (62.5)	2 (25)	1 (12.5) (Fig 3)	0
2 (33.3)	1 (16.7)	5 (83.3)	1 (16.7) ^a	0	0
8 (47.1), 1 (5.9)	0	14 (82.4)	1 (5.9)	0	2 (11.8)
16 (69.6)	1 (4.3)	17 (73.9)	1 (4.2)	2 (8.7)	3 (13)
1	0	1	0	0	1
1	0	1 (100)	0	0	0
3	0	2	0	0	1

Table III. Presentation and management of carotid cavernous fistulae in patients with vascular Ehlers-Danlos syndrome (vEDS)

Age/Sex	COL3A1 variant	Presentation	Management, access site	Length of stay, days, and disposition
49F	c.2131G>A, p. Gly544Ser (missense)	Rupture	Embolization, Percutaneous, 5F, manual pressure closure	7, home, alive at age 63; 14 years follow-up
51M	IVS8+5 G>A (Exon skip)	N/A	Embolization, percutaneous, 5F, manual pressure closure	3, home, alive at age 70
41F	c.2337+2T>C, p.Gly762_Lys779del (splice site)	Ipsilateral retro-orbital pain, blurry vision, and tinnitus	Embolization, percutaneous, 6F, closure with angioseal (Fig 3)	4, home; <1 year of follow-up; died from unrelated complications
42F	Pathogenic	Bilateral	Nonoperative	N/A

F, Female; M, male; N/A, not applicable.

(c.2356G>A, p.Gly786Arg). Of note, this individual had a prior open repair for a ruptured AAA repair at age 33. The patient has had 10 years of follow-up after the procedure without complication.

- **Posterior tibial arteries:** Two patients had posterior tibial artery aneurysms (3.8%); one was managed medically. The other individual was a 19-year-old man with bilateral posterior tibial artery aneurysms (1.5 and 2.0 cm). Open repair with saphenous vein bypass graft was performed for the larger aneurysm. This procedure was complicated by hematoma owing to vein graft disruption, requiring reoperation.

Other rare presentations included involvement of the cerebral and coronary arteries as follows.

- **Cerebral arteries.** Only one individual was affected (1.9%). This was a 39-year-old woman (haploinsufficiency/null mutation) who presented with a left

middle cerebral artery dissection. The dissection was managed medically and she is alive at age 43.

- **Coronary arteries:** There were two cases (3.8%) of coronary artery dissection. One occurred in a 45-year-old woman (c.4360C>T, p.Gln1454Ter) who was initially managed medically, but subsequently underwent coronary artery bypass. She has had 1 year of follow-up without complications. The second case was in a 41-year-old woman (c.2337+2T>C, p.Gly762_Lys779del) who was hospitalized for a spontaneous perforation of the colon. She developed a left anterior descending coronary artery dissection and subsequent cardiac arrest.

Endovascular procedures for medium sized arteries.

Embolization of medium sized arteries was the predominant endovascular procedure performed ($n = 16$ [13.4%]), followed by stenting ($n = 3$ [2.5%]) as described previously. Percutaneous access was used in 14 cases for sheath sizes

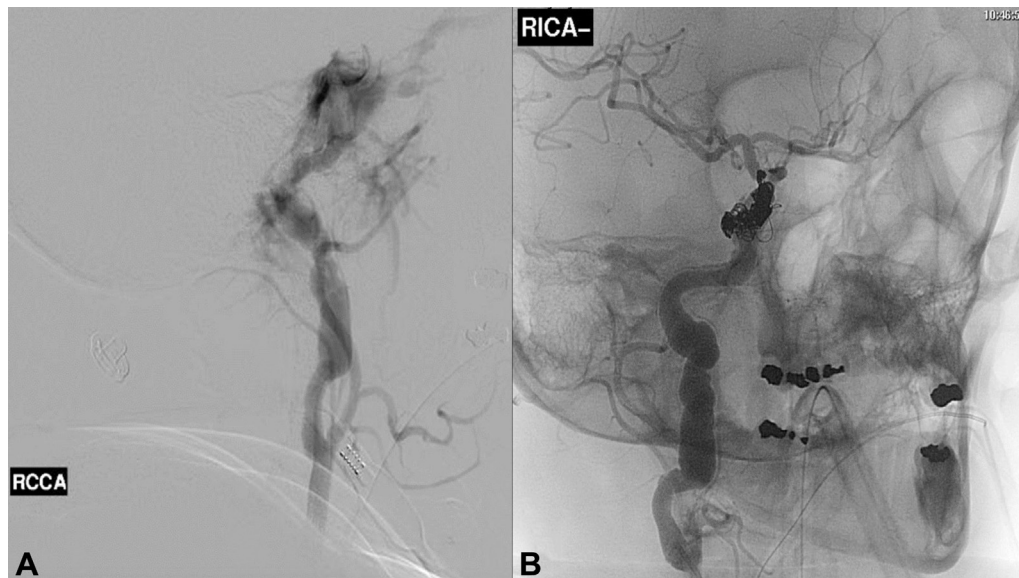


Fig 2. The angiographic findings of a carotid cavernous fistula in a 41-year-old woman with vascular Ehlers-Danlos syndrome (vEDS) owing to a splice site mutation (c.2337+2T>C/p.Gly762_Lys779del) presenting with sudden onset ipsilateral retro-orbital pain, blurry vision, and tinnitus. **A**, Before embolization. **B**, After coil embolization. RCCA, Right common carotid artery; RICA, right common internal artery.

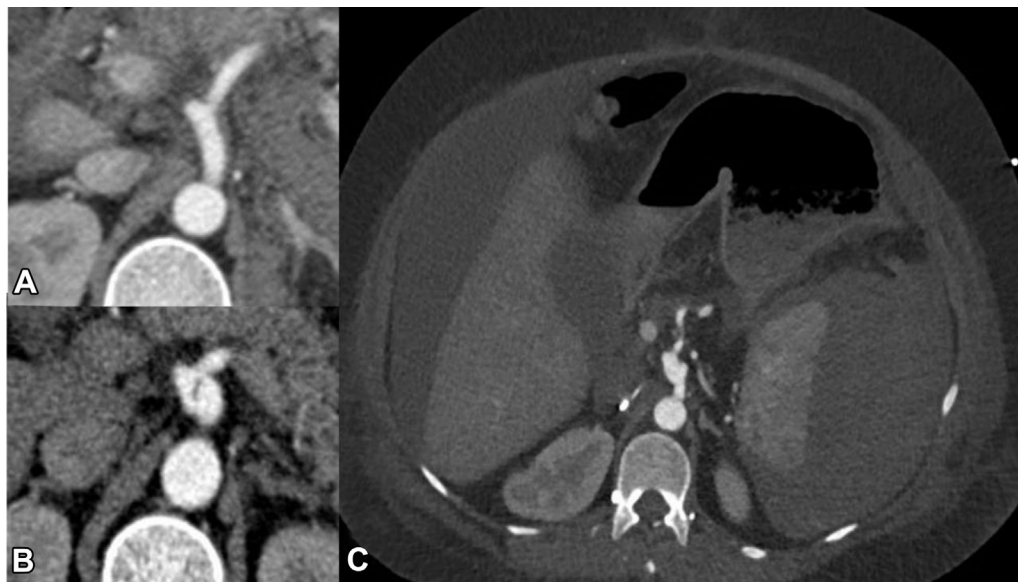


Fig 3. Celiac artery dissection in 36-year-old woman with vascular Ehlers-Danlos syndrome (vEDS) owing to a splice site mutation (c.2337+2T>C/p.Gly762_Lys779del) managed medically. **A**, Axial computed tomography imaging obtained 1 month before the dissection when she presented with a spontaneous hemoperitoneum managed medically. **B**, Axial computed tomography imaging demonstrating focal dissection and mild enlargement of the celiac artery. This remained unchanged on follow-up imaging over the next 5 years. **C**, Axial imaging demonstrating a large spontaneous subcapsular splenic hematoma and hemoperitoneum. This occurred after a complicated hospitalization for perforated sigmoid diverticulitis requiring sigmoid resection, transverse colostomy, and Hartmann's pouch.

of 4F to 7F. Manual pressure after the procedure was used in seven cases (four in which the vEDS diagnosis was not known at the time); the closure was satisfactory in all seven cases, with one (14.3%) hematoma reported. A closure device was used in five cases: Angio-Seal vascular closure device (Terumo Medical Corporation,

Tokyo, Japan; n = 2), StarClose (Abbott Vascular, Santa Clara, Calif; n = 1), Perclose ProGlide vascular closure device (Abbott Vascular; n = 1). All were reported to be successful. Open femoral artery exposure and repair was performed in an additional three cases, with one complicated by hematoma.

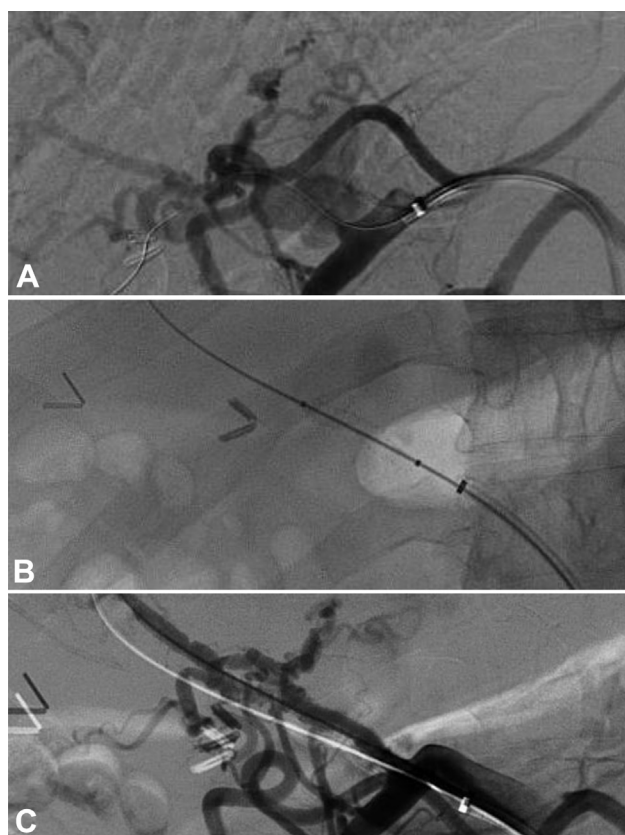


Fig 4. Angiogram showing a proper hepatic artery pseudoaneurysm in a 49-year-old man with vascular Ehlers-Danlos syndrome (vEDS) owing to a haploinsufficiency mutation (**A**). The pseudoaneurysm was excluded with 5.0-mm \times 2.5-cm Viabahn stent (**B** and **C**).

Aortic pathology. Aortic pathology was identified in 17 individuals (32%; 58.8% male; 94.1% Caucasian; median age, 38.5 years; IQR, 30.8-44.7 years). Hypertension was noted in 52.9% ($n = 9$) and smoking in 29.4% ($n = 5$) of the cases. The most common *COL3A1* variant was a missense mutation with glycine substitution with a large amino acid residue ($n = 11$ [64.7%]).

Thoracic aortic pathology was reported in 10 individuals and abdominal aortic pathology was reported in 7 individuals (Table IV). Notably, there were two thoracic endovascular aneurysm repairs (TEVAR) performed for descending thoracic aortic aneurysm ruptures in which the diagnosis of vEDS was unknown at the time. One individual died and the other had a successful repair (Table IV). In one case, an open thoracoabdominal aortic aneurysm (TAAA extent II) was performed successfully in a 19-year-old man with a missense mutation (Table IV).

Among the AAA cases, four individuals underwent successful open AAA repair with excellent long-term follow-up (three had a ruptured AAA; Table IV). In one case, an endovascular aneurysm repair (EVAR) was performed for aortic dissection before diagnosing vEDS. This patient had no short-term complications, with 1 year of follow-up.

Aortic rupture occurred in seven individuals (41.4%) and was the cause of death in two individuals (11.7%): a ruptured type A aortic dissection and a ruptured type B aortic dissection complicated by infectious aortitis.

Mortality. The median follow-up after the first arterial event was 5 years (IQR, 2.5-12.0 years). There were 12 deaths (22.6%) at a median age of 36 years (IQR, 28-51 years; 58.3% male; 83.3% Caucasian). Table V summarizes the characteristics and causes of mortality and Fig 5 shows the Kaplan-Meier estimates of cumulative survival.

Genotype-phenotype correlation. The molecular confirmation in this cohort was performed by genetic testing, showing a pathogenic variant in *COL3A1* ($n = 81$) or by skin biopsy ($n = 5$). Missense mutations with a substitution of glycine with a large amino acid were the most common type of pathogenic variant ($n = 44$ [51.2%]) followed by missense mutations with a substitution of glycine residue with a small amino acid ($n = 12$ [14%]). Null mutations occurred in only seven individuals (8.1%).

Although not statistically significant, individuals with missense mutations in which glycine was substituted with a large amino acid had an earlier onset of aortic/arterial pathology (median, 30 years; IQR, 23.5-37.0 years) compared with the other pathogenic *COL3A1* variants (median, 36 years; IQR, 29.5-44.8 years; $P = .065$). There were no differences between the variant groups in terms of arterial/aortic pathology or rupture.

DISCUSSION

A substantial challenge to evaluating treatment of arterial/aortic pathology in individuals with vEDS is the rare frequency of the disease (1:50,000), such that few centers have any significant experience.^{5,11,12,18} This multi-institutional study is a step in the direction of better understanding the natural history in vEDS and management outcomes.

Several generalizations can be made based on this cohort. Most of the carotid (other than CCF), vertebral, mesenteric, and renal manifestations of the syndrome can be managed medically. When management of arterial manifestations is required owing to spontaneous rupture, enlarging aneurysms, or pseudoaneurysms, an endovascular approach, mostly with coil embolization, and less frequently with stenting, seems to be well-tolerated and these results are consistent with previous reports.^{18,19} Access site management in this series had few complications, including those managed with manual compression and closure devices. This finding is to be interpreted with caution, because we usually recommend open femoral artery exposure and primary repair as previously described^{18,20} for access puncture sites in patients with known vEDS diagnosis, because this method allows for the greatest control of the artery. Although thrombolysis for arterial thrombosis was

Table IV. Presentation and management of aortic pathology in 17 individuals with vascular Ehlers-Danlos syndrome (vEDS)

Age/sex	COL3A1 variant ^a	Location/type	Management	Known vEDS diagnosis	Outcomes
Thoracic aorta (n = 10)					
33M	c.601G>C, p.Gly201Arg	Thoracic aneurysm	Medical	Yes	Died at age 51 from a stroke
44F	c.970G>A, p.Gly324Ser	ATA aneurysm	Medical	Yes	Alive at age 48
37F	c.764G>A, p.Gly255Glu	Ruptured type A aortic dissection	Medical	Yes	Cause of death
79M	c.3320G>A, p.Gly1107Glu	Arch PAU	Medical	Yes	—
40F	c.2222G>A, p.Gly574Asp	DTAA	Medical	Yes	Diameter 4.2 cm; alive at age 41
53M	c.3966delG, p.Lys1323Argfs*64 (null)	TBAD/rupture	Medical	Yes	Cause of death, ruptured owing to aortitis
40M	c.926G>A, p.Gly142Glu	TBAD, mild ATA dilation	Medical	No	Alive at age 49
12M	c.547G>C, p.Gly183Arg	DTAA rupture	TEVAR	No	Discharged home after 2 days; died at age 27 from multiorgan failure
27F	c.1024G>A, p.Gly342Arg	DTAA rupture	TEVAR	No	Cause of death
19M	c.1231G>C, p.Gly244Arg	TBAD	Open repair	Yes	Extent II TAAA repair at age 21; discharged home after 10 days; alive at age 29
Abdominal aorta (n = 7)					
33F	c.996+2G>A, p.Gly318_Pro332del (splice site)	Infrarenal abdominal aortic dissection	Medical	No	Aortic diameter 1.9 cm; alive at age 34
30F	c.1330G>A, p.Gly444Arg	Abdominal aortic dissection	Medical	Yes	—
45M	Pathogenic	AAA/dissection	EVAR	No	Alive at age 46
27M	c.2113G>A, p.Gly705Arg	AAA/dissection	Open repair	No	Discharged home after 8 days; alive at age 31
33M	c.2356G>A, p.Gly786Arg	Ruptured AAA	Open repair	No	Takeback for a ruptured gallbladder; alive at age 51
43F	Pathogenic	Ruptured AAA	Open repair	No	Discharged to rehab after 24 days, wound complicated by infection; alive at age 48
48M	c.3847C>T, p.Gln1283Ter	Ruptured AAA	Open repair	Yes	Take back right limb ischemia; discharged home after 7 days; alive at age 56
AAA, Abdominal aortic aneurysm; ATA, ascending thoracic aorta; DTAA, descending thoracic aortic aneurysm; EVAR, endovascular aneurysm repair; F, female; M, male; PAU, penetrating aortic ulcer; TBAD, type B aortic dissection; TEVAR, thoracic endovascular aneurysm repair.					
^a All are missense mutations unless specifically noted.					

performed in one case in this series, it was associated with a spontaneous hemorrhagic complication. Given the risk of spontaneous hemorrhage, we do not recommend thrombolysis in individuals with vEDS.

CCF embolization seems to offer satisfactory results. This finding confirms previous reports; a referral to a neurointerventionalist is recommended in these cases.^{21,22} Although we did not find a consistent approach for embolization in these cases, the transvenous approach seems to offer a decreased risk of vascular injury.^{21,22}

Iliac arteries dissections without thrombosis can be managed medically, whereas aneurysm repairs are based on association with an AAA. Endovascular stenting

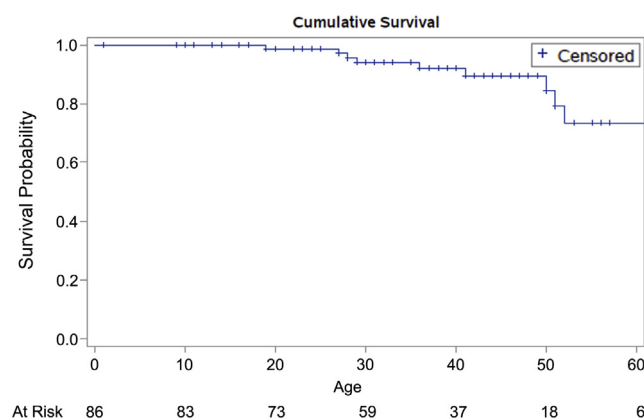
of an aneurysmal iliac artery has been reported to be successful.²³

Several observations can be made in relation to aortic pathology in this cohort. First, aortic disease seems to be more frequent in thoracic segment than in the abdominal differently that the observed frequency in the general population. Given the small numbers, it is difficult to draw any additional conclusions from this observation, but it is worth noting with plans for further evaluation. Second, an open repair of ruptured AAA seems to be as well-tolerated as those without vEDS. Therefore, vEDS should not be a deterrent to offering an operation for a ruptured AAA. We recommend Teflon

Table V. Age and causes of death among 12 individuals with vascular Ehlers-Danlos syndrome (vEDS)

Age/sex	Col3A1 variant	Age					Cause of death
		Diagnosis	Pneumothorax	Colon perforation	Arterial pathology	Arterial rupture	
19M	Pathogenic	19	—	—	19	19	Myocardial infarction with associated ventricular rupture
27F	c.1024G>A, p.Gly342Arg	17	23	—	27	27	Hemothorax
28F	c.2069G>T, p.Gly690Val	23	—	—	23	26	Lateral medullary infarct owing to vertebral artery dissection
29M	c.547G>C, p.Gly183Arg	12	—	—	12	12	Multiple organ failure
36F	c.764G>A, p.Gly255Glu	36	—	—	36	36	Ruptured type A aortic dissection
41F	c.2337+2T>C, IVS34+2T>C, p.Gly762_Lys779del	24	—	36	36	41	Cardiac arrest owing to left anterior descending coronary artery dissection
50F	Pathogenic	32	33	46	38	46	Multiple visceral arteries ruptures
51M	c.601G>C, p.Gly201Arg	29	25	—	33	—	Stroke
53M	c.3966delG, p.Lys1323Argfs*64	43	—	—	36	53	Ruptured type B aortic dissection owing to infectious aortitis
28M	c.2445+2dupT, IVS37+2dupT, p.Gly798_Pro815del	24	22	—	22	—	Unknown
52M	c.1295G>A, p.Gly432Asp	51	—	—	40	50	Unknown
70M	IVS8+5 C>A, p.Gly195_Ser212del	58	—	50	51	—	Unknown

F, Female; M, male.

**Fig 5.** Kaplan-Meier estimates of cumulative survival in individuals with vascular Ehlers-Danlos syndrome (vEDS).

or felt reinforcements for the anastomoses in all aortic repairs. Third, two TEVARs were reported in this cohort (one associated with death) and one EVAR with a short postoperative follow-up duration. These repairs were performed before knowing the vEDS diagnosis. There has been a single case report of successful of TEVAR²⁴

in an individual with vEDS. However, we recommend against the use of TEVAR or EVAR in individuals with vEDS, based on extrapolating from other connective tissues disorders such as Marfan syndrome. TEVAR and EVAR in this population carry a significant risk of use perforation and erosion at the fixation zones, owing to the fragility of the aortic wall, and, with TEVAR, the risk for retrograde aortic dissection.^{18,25}

An interesting finding was the observation of a higher frequency of hypertension and deep vein thrombosis in the patients with vEDS and arterial pathology. We were not able to ascertain if these diagnoses occurred before or after the diagnosis of the aortic/arterial pathology. We also did not ascertain if the affected individuals were taking an antihypertensive. Another interesting finding was the significantly higher frequency of small joint hypermobility in the individuals who did not have arterial pathology, but the significance of this finding is unclear.

We did not find sex differences at initial arterial presentation, similar to what has been previously reported.⁶ Other studies have shown an increased risk of sudden death related to arterial ruptures in males younger

than 20 years.¹⁰ A plausible explanation that unites these disparate findings is the bias toward those who survived to have a diagnosis.

Similar to prior studies, the missense mutations (glycine substitutions) in *COL3A1* were over-represented in this cohort. Missense mutations are the most common type of variant affecting *COL3A1*. The variant results in a substitution of a glycine residue in the Gly-X-Y repeats of the triple helical domain, thus disrupting the type III collagen folding. As a consequence a minimal amount of normal collagen (10%-15%) is excreted from the cell into the extracellular matrix.¹⁴ Similarly, exon skip and splice site variants create a frameshift that results in exon(s) deletion and production of defective collagen similar to the effect of pathogenic missense variants.^{6,16} The biologic explanation is related to the disruptive effect this type of variant has on the type III collagen folding process.^{6,10} Although haploinsufficiency/null mutations lead to the creation of a premature termination codon, the affected gene is essentially silent, resulting in the production of one-half of the amount of normal type III collagen. Thus, missense variants cause a more severe phenotype of vEDS,¹⁰ whereas haploinsufficiency mutations lead to milder phenotype.^{6,9-11} In our cohort, individuals with missense mutations in which the substitution of glycine is with a large amino acid seemed to present with aortic/arterial pathology at an earlier age, compared with the other types of variants, including missense mutations with substitution of glycine with a small amino acid. This finding is plausible; prior work demonstrated an increased disruption of the collagen triple helix when Gly is replaced by a large amino acid rather than by a smaller amino acid.^{6,15} However, our study was underpowered to detect a statistically significant difference and, therefore, replication in a larger cohort is warranted.

We recommend an increased index of suspicion at the time of initial presentation of aneurysms and dissections in young individuals, especially those with a family of aneurysms/dissections and the presence of clinical diagnostic features of vEDS. This finding, then, should lead to confirmatory genetic testing rather than relying on clinical criteria alone for a vEDS diagnosis, given the overlap in clinical features with other forms of Ehlers-Danlos syndrome and other genetically triggered aortopathies.^{4,6} Additionally, understanding the type of *COL3A1* variant allows for counseling on the effect of the variant type on an individual.^{6,9-11,26} Moreover, individuals with an established diagnosis preoperatively have improved outcomes when undergoing elective surgical repairs or interventions compared with those who require emergency operative repair.¹¹ Our work and others substantiate that the genetic testing is no longer experimental or investigational and has real consequences to the affected individual, in terms of surveillance, the operative approaches, perioperative

care, and pregnancy planning. These consequences are relevant to family members as well.

Once the diagnosis is confirmed, we recommend establishing a multidisciplinary care team locally and at a tertiary care center to coordinate care including diagnostic testing, surveillance, and surgical repairs.¹² The care team should include a vascular surgeon, a geneticist, and a primary care provider who organizes the variable levels of care needed by the patient. Baseline arterial imaging should be performed during the initial consultation visits. There are no trials delineating the frequency of surveillance imaging, nor did we ascertain the frequency of imaging in this study. In general, we recommend that surveillance imaging be tailored to the symptoms and presentation of each individual.

This study has several limitations. We did not evaluate the role of medical management in mitigating the risk of aortic/arterial pathology, using beta-blockers, losartan, vitamin C, or adjunctive measures during open repairs such as the use of desmopressin.^{5,27-29} We were also unable to ascertain if the diagnosis of aneurysms and dissections was incidental, made because of surveillance, or because of symptoms. Additionally, the retrospective nature of this study limits our understanding of the decision making used in management or the indication for the elective operations beyond what has been presented in the results. Last, the imaging for all the individuals in this cohort was not available to review in a standardized manner. Review of imaging is highly relevant to understanding the natural history of vEDS and should be included in future study designs.

Future directions include work within the vEDS Research Collaborative to enroll individuals with genetically confirmed vEDS into a large natural history study.³⁰ This study is necessary to obtain detailed longitudinal data to better characterize the natural history and outcomes to guide future management recommendations.

CONCLUSIONS

Most of the arterial manifestations of vEDS were managed medically in this cohort. When intervention is required owing to spontaneous rupture or enlarging aneurysms, embolization (and less frequently stenting) seems to be well-tolerated. Open repair AAA was tolerated and as such, the diagnosis of vEDS should not be a deterrent to offering an operation. Future directions include enrolling patients prospectively into the vEDS Research Collaborative to further ascertain the natural history, elucidate the role of surgical interventions, and to refine management recommendations in the context of patient-centered outcomes.

The authors acknowledge Binod Shrestha (Department of Cardiovascular and Vascular Surgery, at the University

of Texas Health Science Center at Houston) for assisting with data collection at the University of Texas Health Science Center at Houston.

AUTHOR CONTRIBUTIONS

Conception and design: SS, KH

Analysis and interpretation: SS, PB

Data collection: SS, KH, DC, FD, GC, KW, EM, MS, KS, GO, MR, CN, KC, CB, ED, YK, DZ, RP, MP, DM

Writing the article: SS, PB

Critical revision of the article: SS, PB, KH, DC, FD, GC, KW, EM, MS, KS, GO, MR, CN, KC, CB, ED, YK, DZ, RP, MP, DM

Final approval of the article: SS, PB, KH, DC, FD, GC, KW, EM, MS, KS, GO, MR, CN, KC, CB, ED, YK, DZ, RP, MP, DM

Statistical analysis: SS, PB, KH, DC, FD, GC, KW, EM, MS, KS, GO, MR, CN, KC, CB, ED, YK, DZ, RP, MP, DM

Obtained funding: SS, PB, KW

Overall responsibility: SS

REFERENCES

1. Pope FM, Martin GR, Lichtenstein JR, Penttinen R, Gerson B, Rowe DW, et al. Patients with Ehlers-Danlos syndrome type IV lack type III collagen. *Proc Natl Acad Sci U S A* 1975;72:1314-6.
2. Pepin M, Schwarze U, Superti-Furga A, Byers PH. Clinical and genetic features of Ehlers-Danlos syndrome type IV, the vascular type. *N Engl J Med* 2000;342:673-80.
3. Pyeritz RE. Ehlers-Danlos syndrome. *N Engl J Med* 2000;342:730-2.
4. Malfait F, Francomano C, Byers P, Belmont J, Berglund B, Black J, et al. The 2017 international classification of the Ehlers-Danlos syndromes. *Am J Med Genet C Semin Med Genet* 2017;175:8-26.
5. Eagleton MJ. Arterial complications of vascular Ehlers-Danlos syndrome. *J Vasc Surg* 2016;64:1869-80.
6. Frank M, Albuissou J, Ranque B, Golmard L, Mazzella JM, Bal-Theoleyre L, et al. The type of variants at the COL3A1 gene associates with the phenotype and severity of vascular Ehlers-Danlos syndrome. *Eur J Hum Genet* 2015;23:1657-64.
7. Oderich GS, Panneton JM, Bower TC, Lindor NM, Cherry KJ, Noel AA, et al. The spectrum, management and clinical outcome of Ehlers-Danlos syndrome type IV: a 30-year experience. *J Vasc Surg* 2005;42:98-106.
8. Adham S, Trystram D, Albuissou J, Domigo V, Legrand A, Jeunemaitre X, et al. Pathophysiology of carotid-cavernous fistulas in vascular Ehlers-Danlos syndrome: a retrospective cohort and comprehensive review. *Orphanet J Rare Dis* 2018;13:100.
9. Leistritz DF, Pepin MG, Schwarze U, Byers PH. COL3A1 haploinsufficiency results in a variety of Ehlers-Danlos syndrome type IV with delayed onset of complications and longer life expectancy. *Genet Med* 2011;13:717-22.
10. Pepin MG, Schwarze U, Rice KM, Liu M, Leistritz D, Byers PH. Survival is affected by mutation type and molecular mechanism in vascular Ehlers-Danlos syndrome (EDS type IV). *Genet Med* 2014;16:881-8.
11. Shalhub S, Black JH 3rd, Cecchi AC, Xu Z, Griswold BF, Safi HJ, et al. Molecular diagnosis in vascular Ehlers-Danlos syndrome predicts pattern of arterial involvement and outcomes. *J Vasc Surg* 2014;60:160-9.
12. Byers PH, Belmont J, Black J, De Backer J, Frank M, Jeunemaitre X, et al. Diagnosis, natural history, and management in vascular Ehlers-Danlos syndrome. *Am J Med Genet C Semin Med Genet* 2017;175:40-7.
13. Harlander-Locke MP, Lawrence PF. The Current State of the Vascular Low-Frequency Disease Consortium. *Ann Vasc Surg* 2017;38:8-9.
14. Smith LT, Schwarze U, Goldstein J, Byers PH. Mutations in the COL3A1 gene result in the Ehlers-Danlos syndrome type IV and alterations in the size and distribution of the major collagen fibrils of the dermis. *J Invest Dermatol* 1997;108:241-7.
15. Mizuno K, Boudko S, Engel J, Bachinger HP. Vascular Ehlers-Danlos syndrome mutations in type III collagen differently stall the triple helical folding. *J Biol Chem* 2013;288:19166-76.
16. Schwarze U, Goldstein JA, Byers PH. Splicing defects in the COL3A1 gene: marked preference for 5' (donor) splice-site mutations in patients with exon-skipping mutations and Ehlers-Danlos syndrome type IV. *Am J Hum Genet* 1997;61:1276-86.
17. Beighton P, De PA, Steinmann B, Tsipouras P, Wenstrup RJ. Ehlers-Danlos syndromes: revised nosology. Villefranche, 1997. Ehlers-Danlos National Foundation (USA) and Ehlers-Danlos Support Group (UK). *Am J Med Genet* 1998;77:31-7.
18. Brooke BS, Arnaoutakis G, McDonnell NB, Black JH 3rd. Contemporary management of vascular complications associated with Ehlers-Danlos syndrome. *J Vasc Surg* 2010;51:131-8.
19. Okada T, Frank M, Pellerin O, Primio MD, Angelopoulos G, Boughenou MF, et al. Embolization of life-threatening arterial rupture in patients with vascular Ehlers-Danlos syndrome. *Cardiovasc Intervent Radiol* 2014;37:77-84.
20. Lum YW, Brooke BS, Arnaoutakis GJ, Williams TK, Black JH 3rd. Endovascular procedures in patients with Ehlers-Danlos syndrome: a review of clinical outcomes and iatrogenic complications. *Ann Vasc Surg* 2012;26:25-33.
21. Kanner AA, Maimon S, Rappaport ZH. Treatment of spontaneous carotid-cavernous fistula in Ehlers-Danlos syndrome by transvenous occlusion with Guglielmi detachable coils. Case report and review of the literature. *J Neurosurg* 2000;93:689-92.
22. Huynh TJ, Morton RP, Levitt MR, Ghodke BV, Wink O, Hallam DK. Successful treatment of direct carotid-cavernous fistula in a patient with Ehlers-Danlos syndrome type IV without arterial puncture: the transvenous triple-overlay embolization (TAILORED) technique. *BMJ Case Rep* 2017;2017.
23. Tonnessen BH, Sternbergh WC 3rd, Mannava K, Money SR. Endovascular repair of an iliac artery aneurysm in a patient with Ehlers-Danlos syndrome type IV. *J Vasc Surg* 2007;45:177-9.
24. Khalique Z, Lyons OT, Clough RE, Bell RE, Reidy JF, Schwarze U, et al. Successful endovascular repair of acute type B aortic dissection in undiagnosed Ehlers-Danlos syndrome type IV. *Eur J Vasc Endovasc Surg* 2009;38:608-9.
25. Shalhub S, Eagle KA, Asch FM, LeMaire SA, Milewicz DM; Gen TAC Investigators. Endovascular thoracic aortic repair in confirmed or suspected genetically triggered thoracic aortic dissection. *J Vasc Surg* 2018;68:364-71.
26. Schwarze U, Schievink WI, Petty E, Jaff MR, Babovic-Vuksanovic D, Cherry KJ, et al. Haploinsufficiency for one COL3A1 allele of type III procollagen results in a phenotype similar to the vascular form of Ehlers-Danlos syndrome. Ehlers-Danlos syndrome type IV. *Am J Hum Genet* 2001;69:989-1001.

27. Ong KT, Perdu J, De Backer J, Bozec E, Collignon P, Emmerich J, et al. Effect of celiprolol on prevention of cardiovascular events in vascular Ehlers-Danlos syndrome: a prospective randomised, open, blinded-endpoints trial. *Lancet* 2010;376:1476-84.
28. Mast KJ, Nunes ME, Ruymann FB, Kerlin BA. Desmopressin responsiveness in children with Ehlers-Danlos syndrome associated bleeding symptoms. *Br J Haematol* 2009;144: 230-3.
29. Malfait F, De Paepe A. The Ehlers-Danlos syndrome. *Adv Exp Med Biol* 2014;802:129-43.
30. Vascular Ehlers-Danlos Syndrome (vEDS) Collaborative. Available at: www.becertain.org/projects/patient-engagement/vascular-ehlers-danlos-syndrome-veds-collaborative. Accessed May 1, 2018.

Submitted Sep 7, 2018; accepted Jan 23, 2019.